

The Papilla Preservation Flap Surgery: A Review

Dr. Amit Mani¹, Dr. Gowri Pendyala², Dr. Asawari Lawande³, Dr. Amola Patil³

¹Professor, Head, Dept. of Periodontics, Rural Dental College, Maharashtra, India.

²Reader, Dept. of Periodontics, Rural Dental College, Maharashtra, India.

³Post-Graduate student, Dept. of Periodontics, Rural Dental College, Maharashtra, India.

Abstract: A periodontal therapy aimed to establish a state of periodontal health resulted in absence of inflammation, elimination of periodontal pockets and a potential for the patient to maintain the health, function and esthetics. Periodontal surgical therapy used in periodontal defects with maxillary anterior dentition in an esthetic manner is possible only when integrity of the papilla is preserved. This article discusses the different Papilla preservation flap designs and its applications.

Keywords: Conventional papilla preservation¹, Modified papilla preservation², Simplified papilla preservation³ and Whale's tail technique⁴.

Introduction

Objectives of periodontal therapy are :

1. Improvement of the prognosis of teeth.
2. Improvement of esthetics.

The periodontal therapy includes nonsurgical periodontal therapy , surgical periodontal therapy and the correction mucogingival problems. Aim of surgical periodontal therapy is to eliminate pocket and to create a stable, easily maintainable state and to promote periodontal regeneration.

The second objective of the surgical periodontal therapy is the correction of anatomic defects that may favor plaque accumulation and recurrence of the disease.

Most important aspect of the periodontal therapy is the esthetics in maxillary anterior region after pocket elimination therapy. The results of surgical therapy that is gingival recession and interproximal spacing are not acceptable by the patient.¹ In anterior region papilla preservation technique is suggested to maintain the papillary height to maximize postoperative esthetics (Michaelides & Wilson 1996).

Non-surgical approach is most common for maxillary anterior dentition. But in specific cases surgical therapy is the treatment of choice. For obtaining favorable outcome

in periodontal regeneration, primary closure of the osseous defect is essential, or it may compromise clinical attachment gain. The flap is designed in a manner that maximum amount of gingival tissue is preserved to obtain complete coverage of the regenerative material placed in the osseous defect.²⁻⁵ There are various surgical approaches available to obtain primary closure of flap and to preserve interdental tissue.

- A] Conventional papilla preservation technique ²
- B] Modified papilla preservation ³
- C] Simplified papilla preservation flap ⁴
- D] Whale's tail technique

A] Conventional papilla preservation flap

Takei et al. in 1985 introduced conventional papilla preservation technique.

It includes sulcular incisions around each tooth with the lingual/palatal flap involves a semilunar incision made across each interdental papilla that dips apically from the line angles of the tooth so that the papillary incision line angle is at least 5 mm from the gingival margin allowing the interdental tissues to be dissected from the lingual or palatal aspect so that it can be elevated intact with facial flap.²

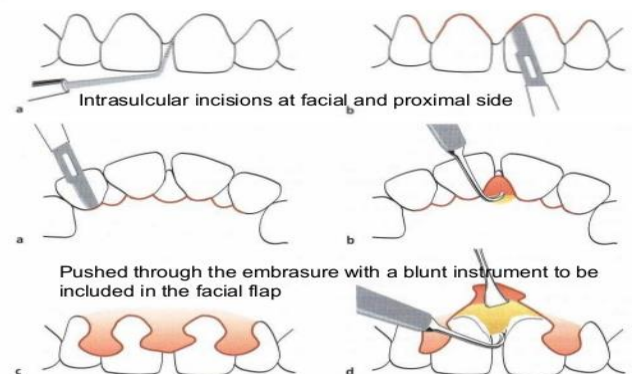


Fig. 1

Cortellini *et al.* (1995, 1996) suggested a modification of the papilla preservation technique.

B] Modified papilla preservation flap

Cortellini *et al.* in 1995 introduced a modification of conventional papilla preservation flap. It was brought in practice by Cortellini as Minimally Invasive Surgical Technique. A horizontal incision is placed buccally on the interdental space at the base of the papilla, and the papilla is elevated toward the palatal aspect. It is mostly suitable for thick interdental papilla in wide interdental spaces.³

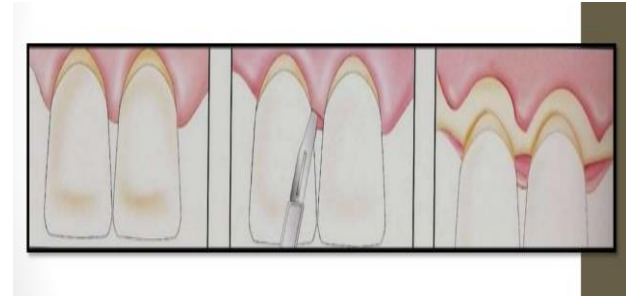

Fig. 3a

Fig. 3b

Fig. 3c

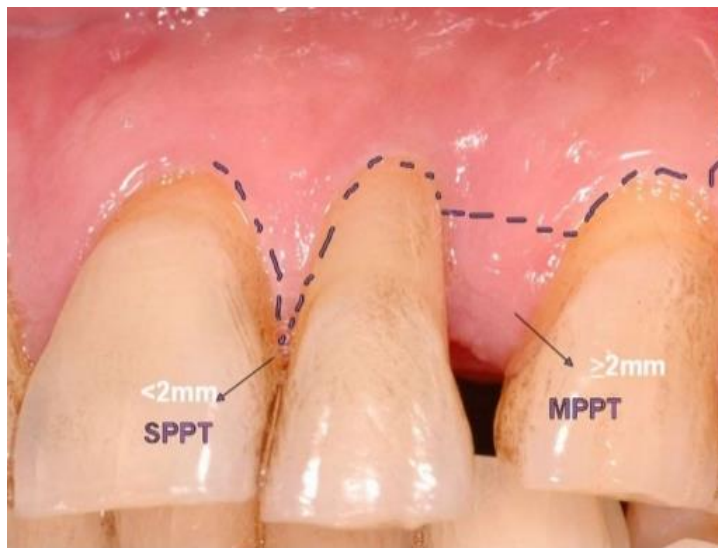


Fig. 2

C] Simplified papilla preservation flap

Cortellini further modified the modified papilla preservation technique which is suitable for narrow interdental spaces (≤ 2 mm). A horizontal incision is replaced by an oblique incision and placed on the buccal aspect of the interdental papilla, and the papilla is elevated toward the palatal aspect.

An oblique incision (Fig 3a) is placed along the defect associated papilla from the gingival margin at the buccal line angle of the involved tooth to reach the mid interproximal portion of the papilla of the adjacent tooth. The oblique incision is continued intrasulcularly in the buccal aspect of the teeth adjacent the defect and extended to partially dissect the papillae of the adjacent interdental spaces allowing the elevation of a buccal flap (Fig 3b) with 2-3 mm exposure of alveolar bone.⁶

D] The “Whale’s tail” technique

Bianchi and Bassetti⁵ in 2009 introduced a surgical technique to preserve interdental tissue in guided tissue regeneration known as a “whale’s tail” technique. It was used for the treatment of wide intrabony defects in the esthetic zone involving the elevation of a large flap from the buccal to the palatal side to allow accessibility as well as visibility of the intrabony defect and to perform GTR while maintaining interdental tissue over grafting material.

Conclusion

During periodontal surgical therapy integrity of the papilla should be maintained. Papilla preservation flap surgery technique maintains esthetic value and a better approach for interproximal regenerative procedures. Conventional and modified papilla flap preservation technique is used for wide interdental spaces in the anterior and pre-molar region and Simplified papilla preservation flap surgery technique can be used in narrow and anterior/posterior interdental spaces to obtain both functional and esthetic value.

References:

1. Cohen E. Cosmetic and reconstructive periodontal surgery, 3rd Ed, p.103
2. Takei HH, Han TJ, Carranza FA Jr, Kenney EB, Lekovic V. Flap technique for periodontal bone implants. Papilla preservation technique. J Periodontol 1985;56:204-10.
3. Cortellini P, Prato GP, Tonetti MS. The modified papilla preservation technique. A new surgical approach for interproximal regenerative procedures. J Periodontol 1995;66:261-6.

4. Murphy KG. Interproximal tissue maintenance in GTR procedures: Description of a surgical technique and 1-year reentry results. *Int J Periodontics Restorative Dent* 1996;16:463-77.
5. Bianchi AE, Bassetti A. Flap design for guided tissue regeneration surgery in the esthetic zone: The “Whale’s tail” technique. *Int J Periodontics Restorative Dent* 2009;29:153-9.
6. Cortellini P, Prato GP, Tonetti MS. The simplified papilla preservation flap. A novel surgical approach for the management of soft tissues in regenerative procedures. *Int J Periodontics Restorative Dent* 1999;19:589-99.